



Pregnancy Before Completion of Follow-Up in Gestational Trophoblastic Neoplasia: a Case Report

Marjaneh Farazestanian¹, MD;  Malihe Hasanzadeh¹, MD; Zohreh Yousefi¹, MD; Fatemeh Homae², MD; Nafiseh Saghafi³, MD; Amir Hossein Jafarian⁴, MD; Parvaneh Layegh⁵, MD; Mansoureh Mottaghi⁶, MD; Laya Shirinzadeh⁶, MD; Leila Mousavi Seresht⁷, MD; Helena Azimi^{1*}, MD 

¹Department of Obstetrics and Gynecology, Fellowship of Gynecology Oncology, Faculty of Medicine, Mashhad University of Medical Sciences, Mashhad, Iran

²Department of Radiotherapy, Faculty of Medicine, Mashhad University of Medical Sciences, Mashhad, Iran

³Department of Obstetrics and Gynecology, Faculty of Medicine, Mashhad University of Medical Sciences, Mashhad, Iran

⁴Department of Pathology, Faculty of Medicine, Mashhad University of Medical Sciences, Mashhad, Iran

⁵Department of Radiology, Faculty of Medicine, Mashhad University of Medical Sciences, Mashhad, Iran

⁶Fellowship of Gynecology Oncology, Faculty of Medicine, Mashhad University of Medical Sciences, Mashhad, Iran

⁷Department of Obstetrics and Gynecology, Fellowship of Gynecology Oncology, Faculty of Medicine, Isfahan University of Medical Sciences, Isfahan, Iran

*Corresponding author: Helena Azimi, MD; Department of Obstetrics and Gynecology, Fellowship of Gynecology Oncology, Faculty of Medicine, Mashhad University of Medical Sciences, Mashhad, Iran. Tel/Fax: +98-5138012477; Email: AzimiHL@mums.ac.ir

Received April 25, 2021; Revised May 5, 2021 Accepted May 25, 2021

Abstract

Introduction: Choriocarcinoma is a rare and malignant tumor, which may present during or following any type of pregnancy. This tumor often demonstrates rapid hematogenous spread to multiple organs and is associated with high levels of human chorionic gonadotropin (HCG) and a good response to chemotherapy. Herein, we introduced a case of metastatic choriocarcinoma who failed to respond to conventional therapies.

Case presentation: A 22-year-old woman referred with vaginal bleeding. The evaluations revealed that she had a metastatic choriocarcinoma that failed to respond to conventional therapies. Continuation of chemotherapy was not possible due to the development of neutropenia. Interestingly, the patient achieved a complete remission spontaneously without receiving further treatment. During the follow-up period, when the patient should not become pregnant, she became pregnant and had no problems during the pregnancy.

Conclusions: Gestational trophoblastic neoplasia is a rare disease. The majority of women suffering from this disease can be cured and their reproductive function could be preserved through the utilization of sensitive quantitation assay for human chorionic gonadotropin (β -hCG) and highly effective chemotherapy.

Keywords: Choriocarcinoma, Metastasis, Chemotherapy

How to Cite: Farazestanian M, Hasanzadeh M, Yousefi Z, Homae F, Saghafi N, Jafarian AH, Layegh P, Mottaghi M, Shirinzadeh L, Mousavi Seresht L, Azimi H. The Pregnancy Before Completion of Follow-Up in Gestational Trophoblastic Neoplasia: a Case Report. Women. Health. Bull. 2021;8(3):189-194. doi: 10.30476/whb.2021.90959.1118.

1. Introduction

Choriocarcinoma is a highly malignant neoplasm that may present during or following any type of pregnancy, including a hydatidiform mole, normal or ectopic pregnancy, and abortion (1).

Gestational choriocarcinoma is a malignant trophoblastic tumor, which arise from any gestational event during the pregnancy in a reproductive female. Women with gestational choriocarcinoma may present with abnormal vaginal bleeding, persistent markedly elevated human chorionic gonadotropin (β -hCG), or a

history of prior pregnancy (2). Accurate diagnosis of gestational choriocarcinoma is crucial since it is a highly chemo-sensitive tumor and the disease exhibits a good prognosis, even in advanced stages (3). Choriocarcinoma is highly invasive and usually metastasizes to the brain and lungs. The most prevalent metastatic sites of choriocarcinoma include the lungs (80%), vagina (30%), pelvis (20%), and liver (10%) (4). Fortunately, choriocarcinoma is fairly chemo-sensitive and despite its aggressiveness, it could be managed with a combination chemotherapy and sometimes surgery (5). Notably, after treatment with multi agent chemotherapy regimens,

~75% of choriocarcinoma patients (FIGO stage IV) are expected to achieve complete or prolonged remission (6). Cases with metastases are harder to manage; on a number of occasions, we fail to achieve a complete remission with usual chemotherapy regimens.

First-line chemotherapy for choriocarcinoma includes EMA/CO (Etoposide, methotrexate, actinomycin-D, cyclophosphamide and vincristine) (7). EMA/CO regimen is highly effective for the treatment of high risk GTN as it exhibits good efficacy and is well tolerated by the patients. Doxorubicin, streptozocin, and 5-fluorouracil combination and TP-EP (paclitaxel, cisplatin/ paclitaxel, etoposide) are the second and third-line therapies (8).

There is little literature on the safety of early pregnancy following chemotherapy. Women who become pregnant within 12 months after chemotherapy for gestational trophoblastic neoplasia (GTN) can be reassured of a likely favorable outcome although the safest option is still to delay pregnancy for one year (9).

We conducted the present work to describe a case of metastatic choriocarcinoma that failed to respond conventional therapies. Continuation of chemotherapy was not possible due to the development of neutropenia. Interestingly, the patient achieved a complete remission spontaneously without receiving further treatment.

2. Case presentation

The patient was a 22-year-old woman referred to Ghaem hospital, Mashhad, Iran with vaginal bleeding, a 2×2 cm mass in the vulva and non-productive cough with β -hCG of 200000 IU/L. She had a missed abortion suspicious of molar pregnancy six months before that, which was managed with dilation and curettage and followed up with β -hCG. Written informed consent was obtained from the patient.

Chest X-ray showed a mass in the middle zone of the right lung. Lung HRCT showed the 60×23 mm STD foci in the pleural base adjacent to the horizontal fissure and a thickening of pleura at the base of the right lung.

The abdominopelvic ultrasound showed a 25×11 mm mass-like lesion at the uterine fundus with bulging towards endometrium and free fluid in the pelvis. The 4 mm hypodense foci were observed in the liver; it was too small to characterize. Brain MRI showed multiple metastatic lesions. She received EMA-CO regimen followed by 20 sessions of brain radiotherapy. She

exhibited seizures during radiotherapy; thus, anti-epileptic medicine was started. Brain MRI showed two hemorrhagic lesions in the left occipital and parietal lobes.

She developed neutropenia during the chemotherapy; accordingly, the treatment was delayed. She received five courses of EMA-CO chemotherapy, yet due to a rise in the β -hCG, a metastasis workup was repeated and EMA-EP regimen was started in September 2017.

The spiral lung and abdominopelvic CT scan showed an 11 mm hypoechoic lesion in the right lobe of the liver and multiple nodules in the pleural base of the right lung. Brain CT scan showed a periventricular hypodensity in the occipital horn of left lateral ventricle (Figure 1: A, B, C). 18 F-FDG PET/CT scan represented a hypo metabolic region in the left parietooccipital region compatible with the previously noted site of involvement. A hypermetabolic region of 26×15 mm in the lower lobe of the right lung with SUV max of 2.94 was observed. No hypermetabolic regions were noted in the liver. The final impression was that the pleural-based pulmonary mass in the right lower lobe is the only possible source for the production of elevated levels of β -hCG and no other active lesions were noted. After receiving three doses of EMA-EP chemotherapy, due to a rise in a β -hCG, the regimen was changed to the TP-TE and a metastasis workup was carried out again (Figure 1: D).

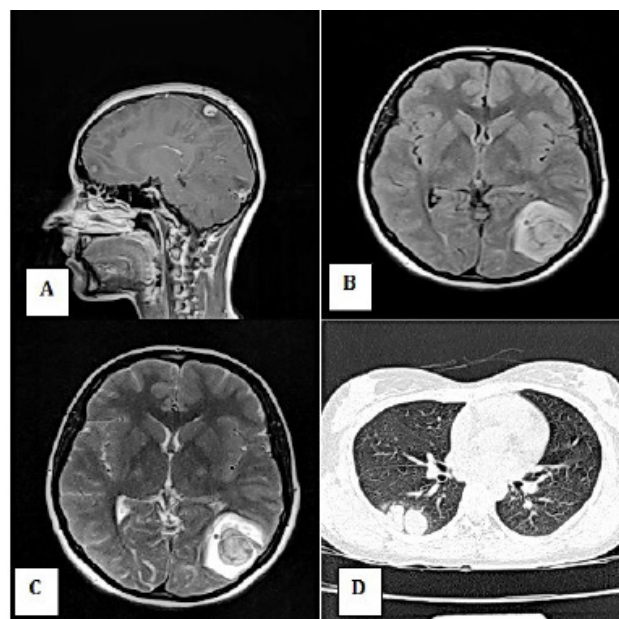


Figure 1: The figure shows a heterogenic mass in the left parietal lobe with peripheral edema in FLAIR and T2W axial images (A and B) and post contrast enhancement (C) suggestive of brain metastasis; adjacent metastatic nodules in the right lung field in lung CT scan (D).

She underwent thoracotomy and wedge resection of the pulmonary lesions in March 2018.

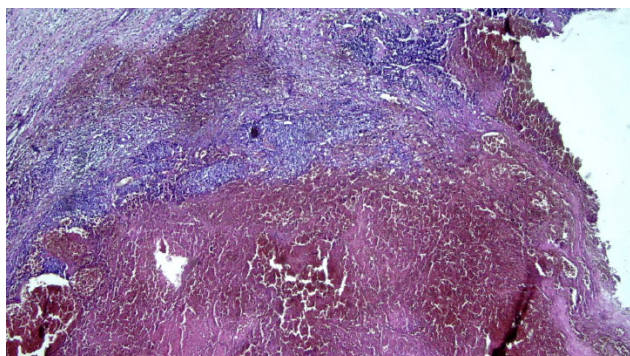


Figure 2: The figure shows a hemorrhagic nodule with fibrotic casing, proliferation of cytotrophoblastic cells, and syncytiotrophoblastic cells (40X zoom).

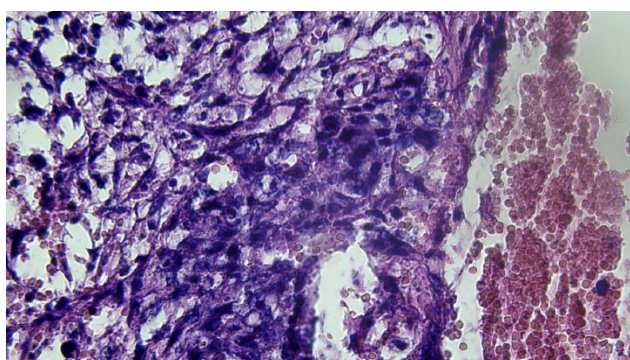


Figure 3: The figure shows proliferation of the cytotrophoblastic cells combined with syncytiotrophoblastic cells (400X zoom).

The pathologic examination confirmed that the lesions are choriocarcinoma metastases (Figures 2, 3). TP-TE chemotherapy regimen was restarted after the thoracotomy. Due to repetitious neutropenia while receiving prophylactic drugs, chemotherapy was halted and restarted for several times (Tables 1, 2, 3). Interestingly, β -hCG became zero spontaneously after not receiving any chemotherapy for two months.

One month after zero β -hCG, despite taking oral contraceptive pills and strict advice against becoming pregnant, she became pregnant. Ultrasound and screening tests were normal at 13th weeks of gestation. Anomaly scan ultrasound at 18th weeks was normal. During the pregnancy, she was followed up through β -hCG, chest x-ray, and abdominopelvic ultrasound up to 20th weeks of gestation. Fortunately, no signs of malignancy were found.

Pregnancy was terminated at 37th weeks of gestation due to the rupture of membranes and vaginal delivery was performed. A male infant was born weighing 3400 gr without anomaly in his appearance. The placenta was sent for pathology, which was normal. B-hCG was zero six weeks after the delivery.

Table 1: Laboratory tests before the treatment

Laboratory tests before the treatment	Result
White cell count (WBC)	3600 mcL PMN65%
Hemoglobin	10.7 g/dL
Platelet	22000 mcL
Aspartate transaminase (AST)	22 u/L
Alanine transaminase (ALT)	17 u/L

Table 2: Laboratory test during the treatment

Laboratory test during the treatment	Result
White cell count (WBC)	4600 mcL PMN60%
Hemoglobin	11.7 g/dL
Platelet	22000 mcL
Aspartate transaminase (AST)	22 u/L
Alanine transaminase (ALT)	28 u/L

Table 3: Laboratory test after the treatment

Laboratory test after the treatment	Result
White cell count (WBC)	2000 mcL PMN 29%
Hemoglobin	11.7 g/dL
Platelet	19000 mcL
Aspartate transaminase (AST)	28 u/L
Alanine transaminase (ALT)	38 u/L

3. Discussion

Choriocarcinoma is a rare gestational trophoblastic neoplasia (GTN) that can arise after normal or, more commonly, molar pregnancy. Despite its aggressiveness and early invasion to adjacent tissues, choriocarcinoma is highly chemo-sensitive. However, when metastasis occurs, the clinical course changes completely and management becomes more challenging, requiring surgery or radiotherapy in addition to chemotherapy. Moreover, the chemotherapy regimen is also multi-drug compared with monotherapy for non-metastatic choriocarcinoma (9).

In the International Federation of Gynecology and Obstetrics (FIGO), scoring system is used to assess the prognosis of patients with GTN and their management. Low-risk patients (FIGO<7) are best managed with a single-agent chemotherapy, usually methotrexate, and the survival rate is around 100%. On the other hand, high-risk patients (FIGO>7) usually require multi-drug chemotherapy and the survival rate is 80 to 90% (10, 11).

In a study on 143 patients with ultra-high-risk gestational trophoblastic neoplasia (FIGO score ≥ 12), 15.9% had relapses after complete remission and 5-year overall survival was 67.9%. The factors associated with worse prognosis were non-molar pregnancy, brain metastases, and failed multi-drug chemotherapy. However, salvage surgery seemed to favor a better prognosis (8).

Surgery can significantly improve the prognosis not only by reducing the tumor burden, but also by removing the drug resistant lesions.

The standard treatment for high risk choriocarcinoma is multi agent chemotherapy. EMA/CO regimen is considered to be highly effective for the treatment of high risk GTN since it exhibits good efficacy and is well tolerated by patients. In the study conducted by Bolis and co-workers, the survival rate of high risk patients treated with EMA/CO regimen was 88%, 76% of whom were alive with no evidence of disease after 5.5 months (12).

An important setback of multi-drug chemotherapy regimens, such as EMA/CO, is the associated side effects; for example, neutropenia is a known adverse effect of chemotherapy and could be managed using G-CSF. However, when severe neutropenia occurs, the best course of action is to halt the chemotherapy until

leukocytes reach a safe level and then restart the chemotherapy. These pauses in chemotherapy courses can significantly affect the management and may result in increased hospital stays and reduce the effectiveness of the therapy (13). Our present patient also experienced several episodes of neutropenia despite administration of G-CSF, which forced us to halt the chemotherapy. Interestingly, after two months of not receiving any chemotherapy or other treatments, β -hCG spontaneously reached zero.

A case report involved a patient suffering from gestational trophoblastic neoplasia and 5-fluorouracil+actinomycin-D chemotherapy. She became pregnant one month after finishing the chemotherapy. No treatments were performed during the pregnancy and she had normal delivery (14).

Hysterectomy is a viable option in patients with low risk choriocarcinoma, who do not want to become pregnant any more. However, hysterectomy is not recommended in patients with metastases because it does not improve the outcome (10). An available surgical option in patients with metastases is metastasectomy, specifically in parenchymal organs, such as lungs and liver. Radiotherapy is also used in patients with brain metastases often in combination with intrathecal methotrexate (11). However, the management of brain metastases is still controversial.

Management of patients with choriocarcinoma is challenging and often requires several courses of chemotherapy and additional treatments, such as surgery and radiotherapy. Moreover, numerous patients develop side effects of chemotherapy that may require additional supportive therapies, like G-CSF or blood product transfusions. Cancer immunotherapy is a novel revolutionary field that has shown a bright future for the treatment of different cancers. A case report of a patient with metastatic choriocarcinoma, who failed to response to known surgical and chemotherapeutic treatments, showed complete durable remission in response to TRC105 (an Endoglin Antibody) and bevacizumab (13). Another patient with chemoresistant metastatic choriocarcinoma showed complete remission in response to Pembrolizumab (a PD-1 antibody) (15).

Different treatment modalities have been employed with varying success. Surgery alone or with chemo and radiation therapy seems to have a better outcome (16). The decision on the best treatment options for each

patient is individualized and requires a multidisciplinary team with adequate experience in gynecologic malignancies. Therefore, these patients should be treated in highly specialized centers with several available specialists.

4. Conclusions

GTN is a rare disease and through the utilization of sensitive quantitation assay for human chorionic gonadotropin (β -hCG) and highly effective chemotherapy; most woman with GTN could be cured and their reproductive function could be preserved.

References

1. Monchek R, Wiedaseck S. Gestational trophoblastic disease: An overview. *J Midwifery Womens Health*. 2012;57(3):255-9. doi: 10.1111/j.1542-2011.2012.00177.x. PubMed PMID: 22587615.
2. Berkowitz RS, Goldstein DP. Current advances in the management of gestational trophoblastic disease. *Gynecol Oncol*. 2013;128(1):3-5. doi: 10.1016/j.ygyno.2012.07.116. PubMed PMID: 22846466.
3. Oranratanaphan S, Lertkhachonsuk R. Treatment of extremely high risk and resistant gestational trophoblastic neoplasia patients in King Chulalongkorn Memorial Hospital. *Asian Pac J Cancer Prev*. 2014;15(2):925-8. doi: 10.7314/apjcp.2014.15.2.925. PubMed PMID: 24568520.
4. Seckl MJ, Sebire NJ, Berkowitz RS. Gestational trophoblastic disease. *Lancet*. 2010;376(9742):717-29. doi: 10.1016/S0140-6736(10)60280-2. PubMed PMID: 20673583.
5. Manopunya M, Suprasert P. Resistant gestational trophoblastic neoplasia patients treated with 5 fluorouracil plus actinomycin D. *Asian Pac J Cancer Prev*. 2012;13(1):387-90. doi: 10.7314/apjcp.2012.13.1.387. PubMed PMID: 22502707.
6. FIGO Committee on Gynecologic Oncology. Current FIGO staging for cancer of the vagina, fallopian tube, ovary and gestational trophoblastic neoplasia. *Int J Gynaecol Obstet*. 2009;105(1):3-4. doi: 10.1016/j.ijgo.2008.12.015. PubMed PMID: 19322933.
7. Lurain JR. Gestational trophoblastic disease II: classification and management of gestational trophoblastic neoplasia. *Am J Obstet Gynecol*. 2011;204(1):11-8. doi: 10.1016/j.ajog.2010.06.072. PubMed PMID: 20739008.
8. Kong Y, Yang J, Jiang F, Zhao J, Ren T, Li J, et al. Clinical characteristics and prognosis of ultra high-risk gestational trophoblastic neoplasia patients: a retrospective cohort study. *Gynecol Oncol*. 2017;146(1):81-86. doi: 10.1016/j.ygyno.2017.04.010. PubMed PMID: 28461032.
9. Williams J, Short D, Dayal L, Strickland S, Harvey R, Tin T, et al. Effect of early pregnancy following chemotherapy on disease relapse and fetal outcome in women treated for gestational trophoblastic neoplasia. *J Reprod Med*. 2014;59(5-6):248-54. PubMed PMID: 24937965.
10. Suzuka K, Matsui H, Iitsuka Y, Yamazawa K, Seki K, Sekiya S. Adjuvant hysterectomy in low-risk gestational trophoblastic disease. *Obstet Gynecol*. 2001;97(3):431-4. doi: 10.1016/s0029-7844(00)01169-8. PubMed PMID: 11239651.
11. Hanna RK, Soper JT. The role of surgery and radiation therapy in the management of gestational trophoblastic disease. *Oncologist*. 2010;15(6):593-600. doi: 10.1634/theoncologist.2010-0065. PubMed PMID: 20495216; PubMed Central PMCID: PMC3227996.
12. Bolis G, Bonazzi C, Landoni F, Mangili G, Vergadoro F, Zanaboni F, et al. EMA/CO regimen in high risk gestational trophoblastic tumor (GTT). *Gynecol Oncol*. 1988;31(3):439-44. doi: 10.1016/s0090-8258(88)80029-5. PubMed PMID: 2846414.
13. Horowitz NS, Elias KM, Goldstein D, Morrissey S, Collins SA, Childress J, et al. Compassionate use study of TRC105 (Endoglin Antibody) in combination with bevacizumab (Bev) in patients (pts) with refractory and metastatic choriocarcinoma. *J Clin Oncol*. 2016;34(15). doi: 10.1200/JCO.2016.34.15_suppl.e17033.
14. Niu G, Yuan LJ, Gong FQ, Yang J, Zhu CX, Shen HW. Early pregnancy following multidrug regimen chemotherapy in a gestational trophoblastic neoplasia patient: A case report. *Medicine*. 2017;96(51):e9221. doi: 10.1097/MD.0000000000009221. PubMed PMID: 29390471; PubMed Central PMCID: PMC5758173.

15. Huang M, Pinto A, Castillo RP, Slomovitz BM. Complete serologic response to pembrolizumab in a woman with chemoresistant metastatic choriocarcinoma. *J Clin Oncol.* 2017;35(27):3172-3174. doi: 10.1200/JCO.2017.74.4052. PubMed PMID: 28742453.
16. Kamata S, Sakurada A, Sato N, Noda M, Okada Y. A case of primary pulmonary choriocarcinoma successfully treated by surgery. *Gen Thorac Cardiovasc Surg.* 2017;65(6):361-364. doi: 10.1007/s11748-016-0666-8. PubMed PMID: 27236469.